

Techniques, Principles and Benchmarks in Asian Blepharoplasty

William P. D. Chen MD

Background: Asian blepharoplasty is a deceptively simple procedure where the goal is to create an upper lid crease. The author presents a retrospective self-analysis of 362 cases performed over the past 12 years.

Methods: 362 cases that fits the inclusion criteria were tabulated into spreadsheet data format. Recorded were age, gender, date of service and follow-ups, whether the AB performed was for primary or revisional purpose; the preoperative lid crease status, the patient-chosen crease height as well as shape preferred. Intraoperative observation included presence or absence of preaponeurotic fat, whether partially resected, or repositioned were noted.

Results: Of 362 patients (724 upper lids), primary AB constituted 81% (295) and revisional AB contributed 19% (67). The gender distribution was 87% female (315) and 13% male (47). The age distribution ranged from 12 to 75 years. The crease height selected ranged from 6.0 to 8.0 mm, with the median being 7.0 mm. Of the crease shape chosen, parallel shape was 65% (236) and nasally-joining crease shape was 35% (126).

Conclusions: Asian blepharoplasty via trapezoidal debulking of preaponeurotic platform is a safe, effective and anatomically-based technique that does not involve the use of permanent buried sutures. The article discussed the 5 essential factors (*aponeurotic attachment*, selective *block* clearance of preaponeurotic space, precise positioning of the *crease* formation loci, detection of latent *droopy* eyelids and avoidance of *Faden-like* suture effect) and the author's benchmarks to achieve a better success rate. Results for primary and revisional Asian blepharoplasty, strategies and potential pitfalls are presented. (請從此看論文摘要: “亞洲双眼皮手術的技術, 原則和基準” <http://links.lww.com/PRSGO/B141>) (*Plast Reconstr Surg Glob Open* 2019;7:e2271; doi: 10.1097/GOX.0000000000002271; Published online 23 May 2019.)

INTRODUCTION

The upper eyelid crease is an anatomical invagination of the eyelid skin along the superior tarsal border.¹⁻⁸ It originates from a complex interaction of vector forces composed of: a healthy levator muscle and Mueller's muscle (posterior layer), the presence of healthy skin-orbicularis over the preseptal region that rolls over passively as a lid fold (anterior layer) and the presence of preaponeurotic fat as the glide layer,⁹ with absence of midlamellar scarring.

In general, Caucasian upper lids with a crease are thinner than their Asian counterparts because of the factors that often include a higher point of fusion of the orbital septum onto the levator, which positions preaponeurotic fat in the upper zone of the eyelid, less preseptal fat and thinner orbicularis oculi. The former possess a greater number of distal fibers of the levator aponeurosis that terminate toward the skin along the superior tarsal border to form the eyelid crease. (Collin,³ Cheng⁴ and Morikawa⁵ in 3 separate articles have verified the presence of myofibrils/microtubules terminating on to pretarsal orbicularis muscles sheaths and subcutaneously beneath the upper lid skin along superior tarsal border.) Levator contraction pulls the tarsus upward and the eyelid crease invaginates easily; whereas the preseptal skin rolls down slightly to form the eyelid fold. Caucasians may often have a suprarsal sulcus distinct from an eyelid crease.

From the Department of Ophthalmology, UCLA School of Medicine, Harbor-UCLA Medical Center, Torrance, Calif.; Department of Surgery (WOS), Aesthetic and Plastic Surgery Institute, UCI College of Medicine, Irvine, Calif.*

Received for publication February 1, 2019; accepted April 5, 2019.

Dr. Chen receives book royalties from Elsevier Sciences, Inc.

Copyright © 2019 The Authors. Published by Wolters Kluwer Health, Inc. on behalf of The American Society of Plastic Surgeons. This is an open-access article distributed under the terms of the Creative Commons Attribution-Non Commercial-No Derivatives License 4.0 (CCBY-NC-ND), where it is permissible to download and share the work provided it is properly cited. The work cannot be changed in any way or used commercially without permission from the journal.

DOI: 10.1097/GOX.0000000000002271

Disclosure: *The patients were selected consecutively and subjected to the exclusion criteria set forth in the paper. The author declares no conflicts of interest.*

Supplemental digital content is available for this article. Clickable URL citations appear in the text

Asians who are monolid typically have thicker eyelids because of the presence of a hypertrophied orbicularis oculi and may have fat in their pretarsal, preseptal and preaponeurotic (postseptal) space. The orbital septum fuses with the levator at a lower position compared with those who possess a crease. There are few or no terminal branches from the levator toward the skin along the superior tarsal border.

The Challenge

The purpose of any Asian blepharoplasty,^{2,10–29} besides adding an eyelid crease, should be to further *improve* on each eyelid's efficiency in its opening and crease formation. It should accomplish this by facilitating (repositioning) those tissue components within the preseptal zone which may help, and by reducing any tissue impediment that works against crease formation. This facilitation can be thought of as 3D remodeling of the preaponeurotic space such that its tissue interaction is more efficient than before. One should be mindful of any actions that adds impedance or *load* to the biodynamics of the eyelids.

PATIENTS AND METHODS

A retrospective analysis of 362 cases of Asian blepharoplasty performed over the last 12 years were studied. The inclusion period were from January 2006 to September 30, 2018, sampling from the author's practice. The study included primary and revisional cases (Fig. 1).

Primary Asian blepharoplasty—defined as first-time upper blepharoplasty with the primary goal of creation of an upper lid crease for a person of Asian descent.

The technique used is detailed in "Trapezoidal debulking of eyelid tissues: application in Asian blepharoplasty."² The goals include placement of a crease to achieve correct *height* and *shape*, also long-term goals to achieve *continuity* (*a continuous crease line*) and *permanence*.

Excluded were conditions that include acquired or congenital ptosis, any type of eyelid retraction or malposition, any strabismus disorders, facial nerve palsy and any neuromuscular disorders. Functional upper blepharoplasty were excluded. Only bilateral cases were tabulated for this series.

For Revisional Asian Blepharoplasty—defined as revision, correction or modification of a suboptimal crease configuration. The most critical in this category are those who present an abnormal high crease with scarce skin left behind. Slightly easier to correct will be those with a rudimentary or partial crease despite an initial attempt; these can be revised through improving the dynamics within the preaponeurotic space. Other correctible cases include those with a crease set too low or high, as long as there are some tissue left to work with such that it will not result in poor closure of the palpebral fissure. In a series of 48 eyelids from 26 patients, the author's³⁰ average lowering of crease height achieved was 2.75 mm.

(The analysis included primary and revisional cases that showed trace to minimal ptosis where the deviation from normal lid position measured no greater than 1.0 mm; in these occasional cases, a levator advancement,

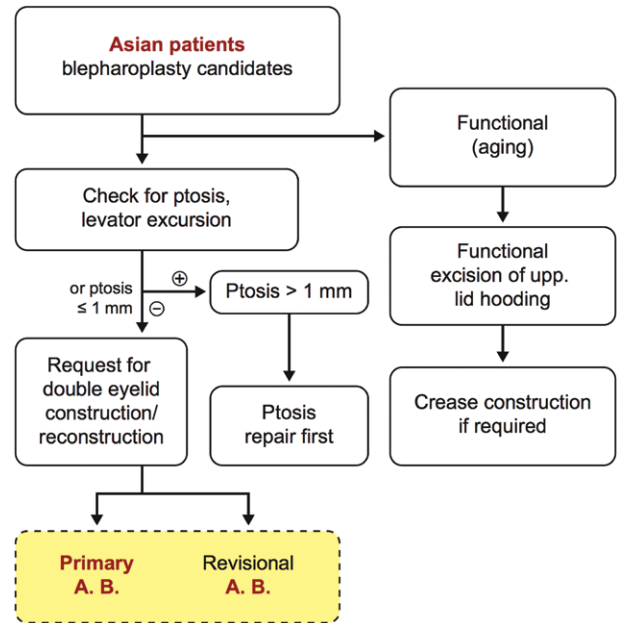


Fig. 1. Clinical pathway showing selection of Asian blepharoplasty cases, both primary and revisional, in this series. (The yellow shaded zone highlights the group of included cases. All others were excluded.)

plication or levator tuck was performed at the same time of the specific procedure for that patient.)

Preoperative Protocol

Most patients underwent the procedure by local anesthesia with oral premedications: 10 mg of diazepam (Valium) and 1,000 mg of acetaminophen (Tylenol) are given within 30–45 minutes before procedure start. Each upper eyelid is infiltrated locally with 0.75–1.0 cc of 2% xylocaine (with 1:100,000 dilution of epinephrine) applied in a sub-orbicularis plane, using #32 gauge ½" needle.

For primary cases, the steps are shown in **SDC 1**³¹ (see video, Supplemental Digital Content 1 which displays Asian upper blepharoplasty, <http://links.lww.com/PRSGO/B79>).

For revisional cases, the steps are shown in **SDC 2**³² (see video, Supplemental Digital Content 2 which displays Asian upper blepharoplasty Part 2, <http://links.lww.com/PRSGO/B80>).

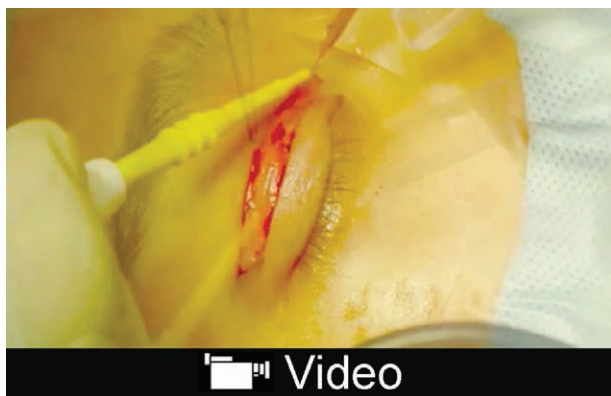In all cases, the wound closure was through skin-aponeurosis-skin.

Postoperative treatment recommendations—patients are advised to have bed rest the first day, cold compresses are applied locally for the first day and topical antibiotic ointment are used 4 times daily for 1 week. All sutures are removed after 1 week.

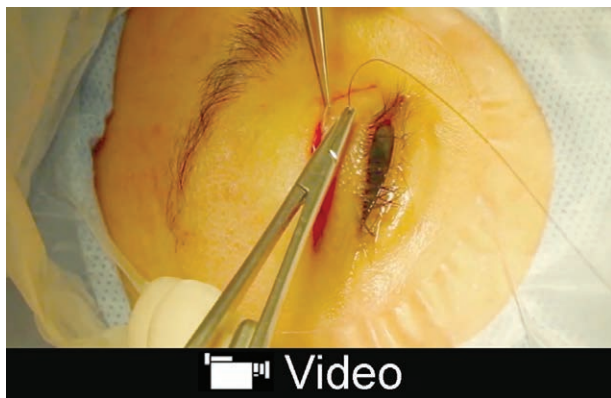
The patients were drawn exclusively from the author's private practice and were not part of any teaching services related to university or hospital and are therefore not under any Institutional Review Board approval.

RESULTS

The age distribution ranged from 12 to 75 years. The most common age group was from 20 to 30 years, although



Video Graphic 1. See video, Supplemental Digital Content 1, which displays Asian upper blepharoplasty. This video is available in the “Related Videos” section of the Full-Text article on PRSGlobalOpen.com or at <http://links.lww.com/PRSGO/B79>. Primary Double Eyelid Surgery—Trapezoidal Debulking of Upper Eyelid Tissues (*Plastic and Reconstructive Surgery—Global Open*. May 2018;6:e1780. doi:10.1097/GOX.0000000000001780).



Video Graphic 2. See video, Supplemental Digital Content 2, which displays Asian upper blepharoplasty Part 2. This video is available in the “Related Videos” section of the Full-Text article on PRSGlobalOpen.com or at <http://links.lww.com/PRSGO/B80>. Revisional Asian Blepharoplasty—Bevelled Approach and Resetting of Eyelid Lamellas (*Plastic and Reconstructive Surgery—Global Open*. August 7, 2018;6:e1785. doi:10.1097/GOX.0000000000001785).

it spread fairly evenly across the 30–60 years old spectrum. Two cases were tabulated as 12 and 15 years of age; both were precocious women, with Asian and European heritage and going into performing arts school training as their choice of vocation (Fig. 2A).

The gender distribution was 87% female (315) and 13% male (47) (Fig. 2B). Primary AB constituted 81% (295), whereas revisional AB contributed 19% (67) (Fig. 2C). The crease *Height* selected (Fig. 3) ranged from 6.0 to 8.0 mm, with the median being 7.0 mm (~49%); this being the most natural and physiological anatomic crease height. Slightly below-average crease height of 6.5 mm was the next most chosen height design, followed by slightly above-average crease height of 7.5 mm. In 19 cases (~5%), 8 mm was chosen (1 mm higher than average) for people that showed European–Asian ancestry or features.

Of the *Shape* of crease chosen (Fig. 2d), parallel shape was 65% (236), and nasally joining crease shape was 35% (126). The author provided neutral comments and refrained from suggesting one crease shape over the other, preferring that the individual make their choice.

Fat Management

Among 295 *primary* cases for double eyelid surgery, 73% (214 cases) had intraoperatively observable preaponeurotic fat (represented as yellow and green pies in Fig. 4). Among these 214 cases with fat, 54% (115 cases) had these fat partially reduced through controlled excision. Among all primary cases, 39% (115 cases) underwent some form of fat reduction.

Among *revisional* cases (67), 63% (42 cases) had residual fat, and 16 among these 42 (38%) underwent further fat reduction. Among all revisional cases, 24% underwent fat reduction; this is lower than that seen among primary cases since their prior surgeries likely reduced their fat content.

There were 34 revisional cases (50%) where the main issue was failure of crease formation; and among these, some required clearance of residual preaponeurotic fat.

Among the 67 revisional cases referred in for correction:

- 34% (23) were for adjustment of CREASE DOWNWARD, which is more difficult;
- 15% (10) were for adjustment of CREASE UPWARD, and
- 51% (34) were to correct for absence of crease.

All *adjusted crease height* remained at the set crease height when measured at 2 months and within 1 year postoperatively.

Suboptimal Results and Complications

Among 295 primary cases from author’s own practice (590 eyelids), 11 cases (15 eyelids) needed touch-up revision, with a revision rate of 2.54%. Among these, 13 lids (87%) were performed to deepen a crease set that have become shallow or rudimentary. Two eyelids from 2 cases (13%) were performed to excise some residual skin or fullness above the set crease. None of these touch-ups had required resetting from a crease that was placed too high from our primary procedure. None of the 11 had any significant keloid reaction.

Of the 67 cases (134 eyelids) referred in for revisional Asian blepharoplasty, one patient underwent a further touch up (both sides) by us 1 year later. This case’s circumstance was unusual as she developed midface swelling upon dental extraction within 2 weeks of her eyelid procedure. The pretarsal segment re-expanded markedly, and her crease height were shifted up permanently even after a year. Our resultant touch-up rate among this referral group after 1 year is therefore 1.5%.

DISCUSSION

Chen^{9,33} discussed the role of the preaponeurotic fat (central fat) in the function and dynamics of the upper eyelids. In this study, the following are the factors considered most critical for success in Asian double eyelid surgery.

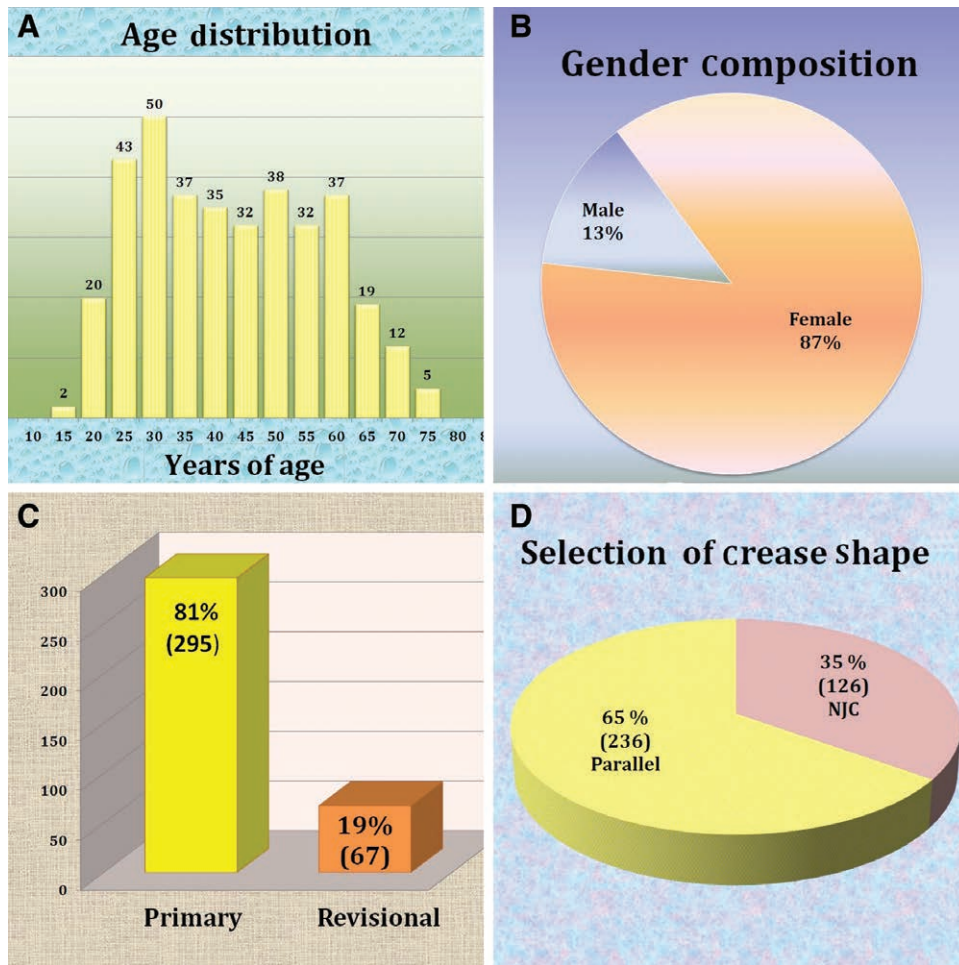


Fig. 2. A, Age distribution: the age distribution ranged from 12 to 75 years. The most common age group was from 21 to 30 years, although it spread across the 30- to 60-year-old spectrum. (Each bar includes a 5-year range that comprises those aged within 5 years up to that indicated age at the bottom of the bar.) B, Gender: 315 cases were women (87%), and 47 were for men (13%). C, There were 295 cases of primary Asian blepharoplasty (81%) and 67 cases for revisional Asian blepharoplasty (19%). D, Selection of crease shape: 65% (236) chose parallel crease shape, whereas 35% (126) chose nasally joining shape.

Aponeurotic Attachment to Skin along the Superior Tarsal Border

To create the eyelid crease, it does *not* require a complete encircling of the levator-Mueller muscles complex (Fig. 5).^{2,33} This false step often produces a ligature-induced crease indentation yielding a static, harsh crease. One only need to direct a fraction of the levator aponeurotic fibers to the under-surface of the skin* along the superior tarsal border to be effective; this yields a natural, dynamic crease.

Listed here are the author’s interpretation of Levels of Attachments during eyelid crease construction:

- Level 1: Skin-to-skin closure, seldom yields a crease.
- Level 2: Skin-inferior orbicularis oculi-skin anchoring: fair, though unpredictable outcome at crease formation.
- Level 3*: Skin-aponeurosis-skin closure (dynamic).
- Level 4: Skin-tarsus-skin closure (static).

Level 5: Skin-tarsus & incorporate orbicularis-to skin closure using either dissolvable or permanent buried sutures (deeper, static crease).

Level 6: Use of encircling element around anterior and posterior lamella/ buried sutures techniques (permanent non-absorbable)—yields static crease and apparent dimpling of skin can be seen on downgaze in some cases.

Benchmark

One should avoid the use of any permanently buried, anchoring stitches whether partial thickness, or encircling the levator-Mueller’s layers in a full-thickness fashion.

Block Resection (Trapezoidal Debulking) of Redundant Anterior Lamella is Essential for Long-term Success

Using a beveled approach, redundant tissues are selectively removed in a clean trapezoidal cross-section (Fig. 6).^{2,34-40} This lightens the impedance from the anteri-

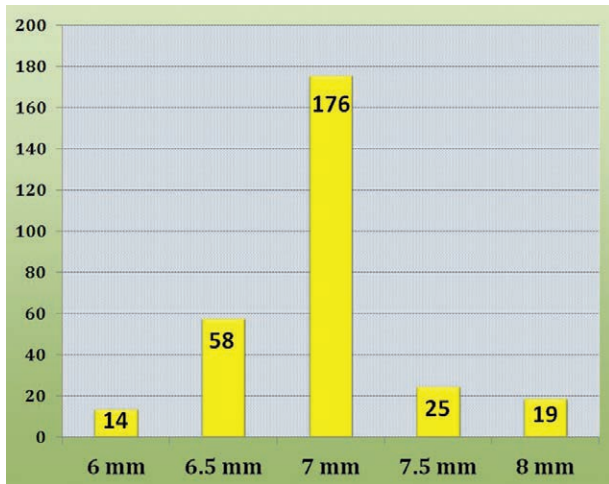


Fig. 3. Upper lid crease height design. The crease height selected ranged from 6.0 to 8.0 mm, with the median being 7.0 mm (~49%). Slightly below-average crease height of 6.5 mm was the next most chosen height design, followed by slightly above-average crease height of 7.5 mm.

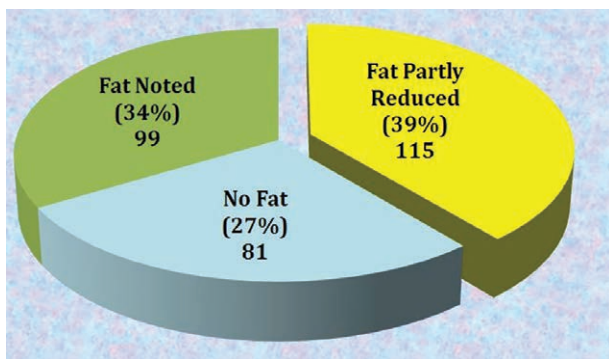


Fig. 4. Treatment of preaponeurotic fat in primary Asian blepharoplasty (295 cases, 590 eyelids). Among these, 73% (green +yellow pies: 214 cases) had observable fat intraoperatively. Of these 214 cases with fat seen, 54% (115 cases; yellow) underwent partial reduction of preaponeurotic fat. Among 295 cases, 39% (115 cases) had undergone some form of fat reduction.

or lamella (skin, orbicularis oculi and preaponeurotic fat) and create a greater space just above the superior tarsal border. This facilitates crease invagination and the natural relaxation of lid fold above it.

Benchmark

Before closing the wound and without any sutures, I need to see a well-formed crease as I instruct the patient to lift the upper lid, to check on the efficiency of the levator in forming the crease.

Critical Crease-positioning

Conceptually there exists a dynamic force-reversal point, where the posterior and anterior lamellae interact along the superior tarsal border to form the crease.^{9,33,41-46} I think of it as a series of nanoscopic “uni-point”, each as a “nanosphere” that rotates between the lid fold and the tarso-levator-Mueller’s muscle.^{9,33,41-46}

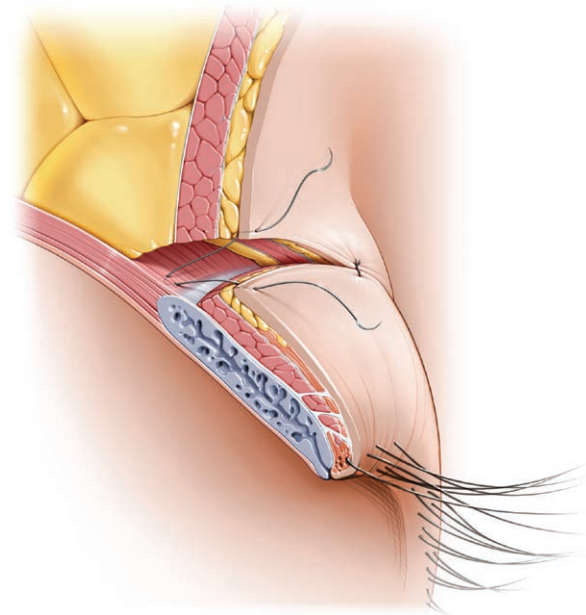


Fig. 5. The crease construction is facilitated through placement of interrupted sutures, each directing a superficial portion of levator aponeurotic fibers along the superior tarsal border toward the upper and lower skin edges of the lid crease incision (Reprinted from “Chen WPD. Asian Blepharoplasty and the Eyelid Crease. 3rd ed. Elsevier Science; 2016”).

(Septoaponeurotic^{41,42,43,46} closure may act similarly near this anatomic region.)

To position the crease higher than ideal position will risk high anchoring with resulting lagophthalmos, high crease and asymmetry. It reduces levator muscle’s contractility due to increased load (impedance) from carrying a greater amount of skin and orbicularis, eventually manifesting as a mild secondary ptosis.

To position the crease lower than ideal position will run the risk of not forming a crease as there will be less interplay between the two lamellae at the critical locus along the superior tarsal border. One often sees fading of crease, and poorly concealed incision scar in a low, pretarsal exposed position.

The upper tarsus is normally tilted at 40–50 degrees from the horizontal when the subject is sitting and looking ahead, with eyes open and the lid margin resting along the superior limbus, covering 1 mm of cornea.³³ If we should assume the tarsal-tilt angle in vivo as 45 degrees (verified by mathematical modeling and MR imaging scan³³) and the tarsal height at its mid-point is measured as 7.0 mm, it has a vertically observed Tilted crease height (*Tch*) that is calculated to 5.0 mm (Fig. 7, blue line). With this tarsal-tilt angle, there is a 5:7 equivalence ratio between *Tch* and anatomic crease height (measured with lids closed, or tarsus everted). What we see as a 5 mm double eyelid crease when observed face-on (as *Tch*) will require a 7 mm anatomical crease design during Asian blepharoplasty.

Benchmark

I regularly check my crease placement, measuring it multiple times. A Castroviejo caliper with half-millimeter

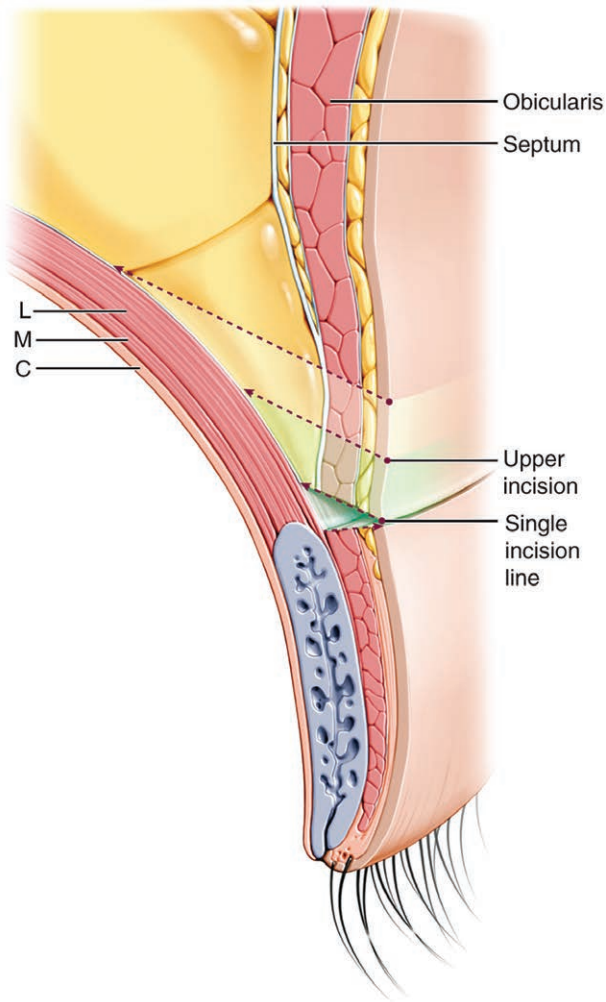


Fig. 6. The concept of trapezoidal and triangular debulking of eyelid tissues as applied in Asian upper blepharoplasty. The beveled approach allows a selective removal of those tissues which may be impeding crease construction, and optimally aligns the wound for closure. After making the initial lid crease incision along the superior tarsal border (STB), plus an upper skin incision separated from it by 1.5–2 mm of skin, the upwardly-beveled trans-orbicularis arrow and returning vector (along the STB) represent the asymmetric sides of a conceptual trapezoid, with the skin and anterior surface of aponeurosis being the two remaining sides essentially running parallel to each other. Based on limited skin removal, the excision of soft tissues (skin, orbicularis, septum and fat) can be performed in an elegant, trapezoidal block. This permits a greater surface of the aponeurosis to be cleared (Reprinted from “Chen WPD. *Asian Blepharoplasty and the Eyelid Crease*. 3rd ed. Elsevier Science; 2016”).

increments (0.5mm) is used to mark the incision lines. Crease positioning influences the final outcome including the *Height* and *Shape* of the crease, and whether the crease appears natural or harsh. (see the “*Aponeurotic Attachment to Skin along the Superior Tarsal Border*” section).

Decreased Levator Function (LF) and Latent Ptosis (Droopy Eyelid) Are Commonly Missed

A ptotic lid covers more of the cornea.^{47–53} Even if that person shows the same levator excursion as a nonptotic

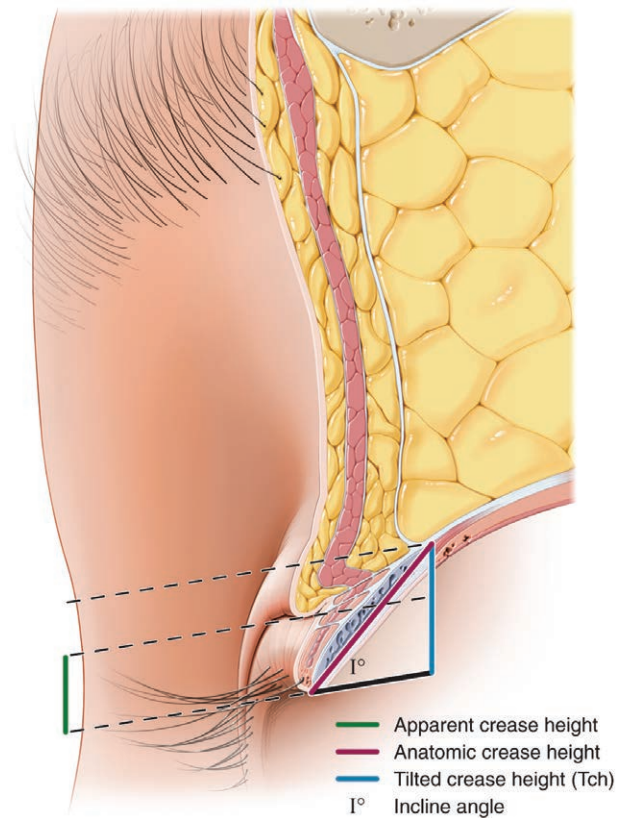


Fig. 7. Drawings illustrating the concept of Anatomic crease height represented by the purple line spanning the actual dimension of the tarsal plate; and Tilted crease height (Tch, in blue vertical) represents the vertical visual component of the tilted tarsus when observed frontally. When there is a lid fold partly shielding the crease, the segment of pretarsal skin we see exposed frontally is measured as the Apparent Crease height (green, vertical). Neither the Tch nor the apparent crease height represents the true extent of the anatomic crease height (Reprinted from “Chen WPD. *Asian Blepharoplasty and the Eyelid Crease*. 3rd ed. Elsevier Science; 2016”).

person, it is inadequate in fully invaginating a crease during construction. When detected, ptosis needs to be repaired as this restores a better “null-point” position for eyelid crease invagination.

Benchmark

Even mild 1–2 mm ptosis should be separately corrected before any attempt to create a double eyelid crease.

The Matter of Epicanthoplasty: A Case of Excessive Use?

It is a mistake for benign medial upper lid fold which has not entirely blocked the view of the caruncle, to be labeled as epicanthal fold.^{54–58} There is a liberal use of the term “epicanthoplasty”^{55–58} which has exposed surgical trainees into thinking that reduction of the medial upper lid fold requires a separately labeled procedure of epicanthoplasty. One can plainly observe that the myriads of papers on epicanthoplasty techniques⁵⁵ published are all miniscule treatments of small dog-ears, and all reported success.

Benchmark

Medial upper lid fold are eliminated during Asian blepharoplasty, through strategic undermining above the medial canthus and removal of skin fold and orbicularis oculi muscle, without the need for “flap” creation beyond the medial commissure. This is accomplished while designing for a nasally joining crease (NJC, “inner”, closed end); or a parallel (“outer”, nontouching) crease *shape* (Fig. 8). Recently, the author has applied up-knotting (for parallel crease shape) and down-knotting (for nasally joining crease shape) of the medial-most single stitch on the skin incision following medial fold reduction,³⁹ which has helped with stability of the crease shape.

Faden Concept: One Should Not Create Faden-like Effect

Posterior fixation^{59–61} with Faden (*German, for suture*) is an occasionally used strabismus surgery for treatment of large-angle congenital esotropia (crossing of eyes).^{59–66} The procedure fixates the proximal region of the medial rectus to the globe through intrascleral stitches, combined with proximal recession to weaken its axial pull in esotropia.

The levator’s contractility can be similarly impaired by more proximal (toward orbital apex) linkage of the skin–orbicularis lamella toward the levator aponeurosis (creating a higher eyelid crease), or deeper-than-normal placement of skin/orbicularis-to-levator fixation sutures (**Video 3**; Figure 9); this is similar to Faden-ing in strabismus repair, except that the hindrance for the levator aponeurosis here is toward the *overlying* skin–orbicularis (an “ecto-Faden-like” effect; see video, Supplemental Digital Content 3, which demonstrates higher-than-average crease placement and its restrictive (impeding) effect on levator muscle excursion, in a routine functional upper blepharoplasty for a 49-year-old Caucasian female, <http://links.lww.com/PRSGO/B81>). Koornneef^{62,63} has shown that the human orbit contains fibroconnective tissue septae that envelops all the extraocular muscles; these septal fibrosis can cause entrapment syndrome following orbital fracture.

Recently, Clark et al^{64–66} has demonstrated the effect of orbital fat pulley and its measurable tethering effects. By stitching the medial rectus’s upper and lower edges to small amount of surrounding orbital fat *alone*, he can replicate the posterior fixation with Faden procedure’s weakening effect, thus avoiding any increased risk associated with needle penetration through sclera (**Video 4**) (see video, Supplemental Digital Content 4, which displays surgical steps involved in medial rectus recession coupled with linking the muscle to adjacent orbital fat and connective tissues, in a 3-year-old child with congenital esotropia. It achieved similar impeding effect as posterior fixation with Faden suturing technique, but without the need for placement of intrascleral sutures and its associated risks, <http://links.lww.com/PRSGO/B82>). One can conclude that extraocular muscles such as medial rectus and even the larger levator muscle are susceptible to weakening (**Video 3**) when anchored with multiple sutures to surrounding tissues it is not normally bound with (Figure 9).

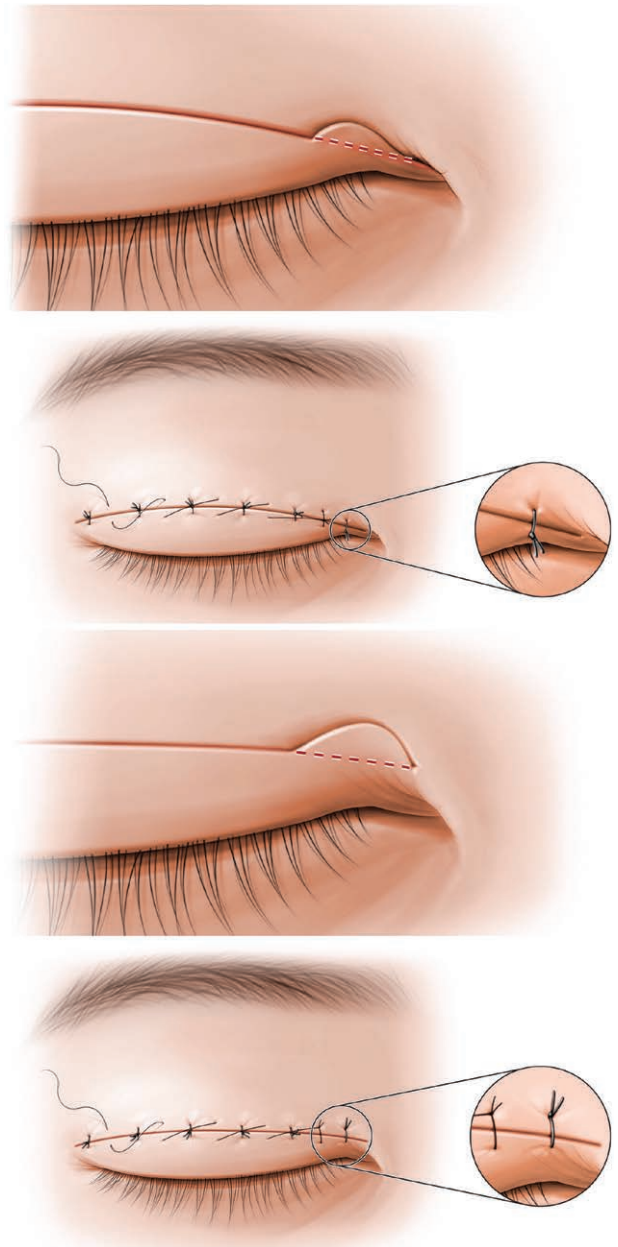


Fig. 8. Treatment of incidental findings of medial upper eyelid fold. Undermining of redundant tissues followed by excision of orbicularis oculi, and overlapping dog-ears as applied in construction of a nasally joining crease shape (top 2 diagrams), and in parallel crease shape (lower two diagrams); note the deliberate placement of the medial-most suture knot inferior to the incision edge (down-knotting) for nasally joining crease shape, and on the upper border (up-knotting) for creating parallel crease shape (Reprinted from “Chen WPD. *Asian Blepharoplasty and the Eyelid Crease*. 3rd ed. Elsevier Science; 2016”)

When tethered, the levator will show a failure to invaginate a crease properly if the tissue adhesion is permanent and nonreleasing with its decrease in levator excursion (contractile travel). Over time, one often observes ptosis in postblepharoplasty patients. The fortunate ones are those where the permanent sutures cheese-wire through the tissues, and in effect releases themselves spontaneously.

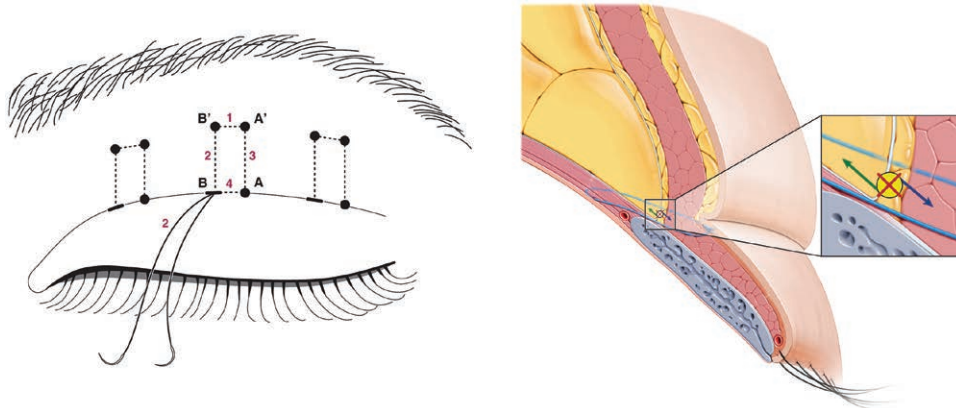
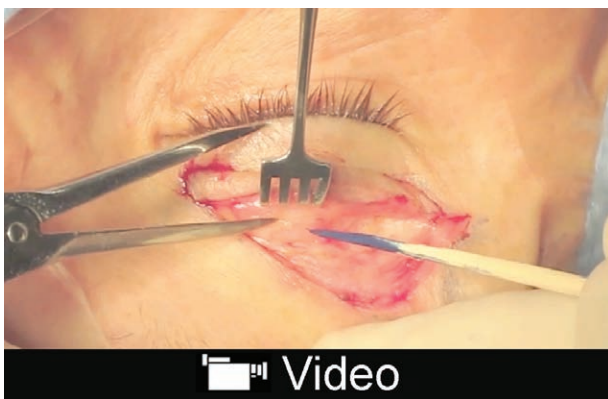
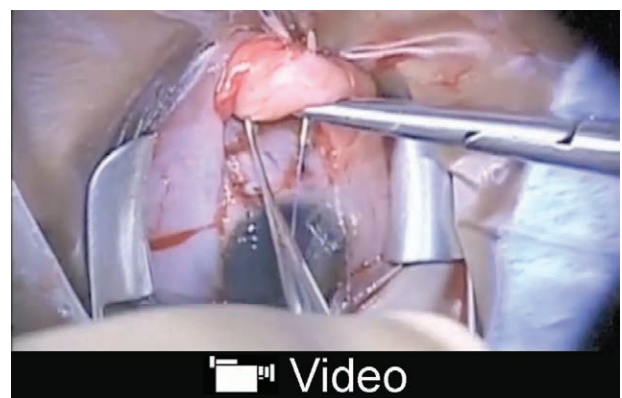


Fig. 9. Drawings showing placement and passages of permanent buried suture loops. **a**, Traditionally the suture methods uses three sets of double-armed 7-0 nylon or prolene. The drawing shows the typical passages for the central set of buried suture(left upper lid). The first passage (step 1) involves everting the upper lid margin and passing it subconjunctivally for 3–4 mm across (A'–B') at a level typically several millimeters above the superior tarsal border, further up and behind the levator aponeurosis. The second passage (step 2) directs one needle toward the skin side along the path of B'–B, aiming just over the upper border of the tarsus. Similarly for the other arm of the suture, the third passage (step 3) goes from A' to A. If each of the suture threads are tied on the skin at this moment, it will be a full thickness compression ligature encompassing Muller's muscle, levator aponeurosis and orbicularis oculi muscle in a postero-superiorly biased fashion along the axis of levator muscle's contractility. In addition to a plication effect on the aponeurosis, it inadvertently creates a "Faden-like effect" at each of the two locations of B'–B and A'–A. In actuality the second needle exiting the skin at A (after step 3) is re-passed (step 4) subcutaneously across to join B, exiting at a mini-stab skin opening there. The nylon ends are "firmly tied" and the knot sunken into the small surgical opening. In addition to the Faden-like effect, this results in a horizontal contraction in the width of levator aponeurosis at the two locations of A'–B' and A–B. With three sets of sutures, the restrictive effect is tripled (Reprinted from "Chen WPD. *Asian Blepharoplasty and the Eyelid Crease*. 3rd ed. Elsevier Science; 2016"). Right, **b**, Cross section showing placement of buried suture that encircles the orbicularis oculi, levator aponeurosis and underlying Mueller's muscle. Here it is shown as a blue 7-0 nonabsorbable suture loop. The nanospheres mentioned in the "Critical Crease-positioning" section is shown as a magnified yellow nanosphere here, is constrained in its phasic-reversal function; as the linkage of different layers added load to the levator when it contracts (causing ecto-Faden-like weakening effect for the levator on the long term), and tethering the anterior orbicularis to a higher point on the posterior levator muscle (one can say that here it is creating endo-Faden-like effect for the orbicularis oculi). The orbicularis oculi normally functions to shut the eyelid fissure, therefore locking it together with levator, which is an elevator/opening muscle makes the orbicularis work harder to close the lid fissure (Reprinted from "Chen WPD. *Asian Blepharoplasty and the Eyelid Crease*. 3rd ed. Elsevier Science; 2016").



Video Graphic 3. See video, Supplemental Digital Content 3, which demonstrates higher-than-average crease placement and its restrictive (impeding) effect on levator muscle excursion, in a routine functional upper blepharoplasty for a 49-y-old female. This video is available in the "Related Videos" section of the Full-Text article on PRSGlobalOpen.com or at <http://links.lww.com/PRSGO/B81>.



Video Graphic 4. See video, Supplemental Digital Content 4, which displays surgical steps involved in medial rectus recession coupled with linking the muscle to adjacent orbital fat and connective tissues, in a 3-y-old child with congenital esotropia. It achieved similar impeding effect as posterior fixation with Faden suturing technique, but without the need for placement of intrascleral sutures and its associated risks. This video is available in the "Related Videos" section of the Full-Text article on PRSGlobalOpen.com or at <http://links.lww.com/PRSGO/B82> (Edited from video, courtesy of Robert Clark M. D. of Long Beach, Calif.).

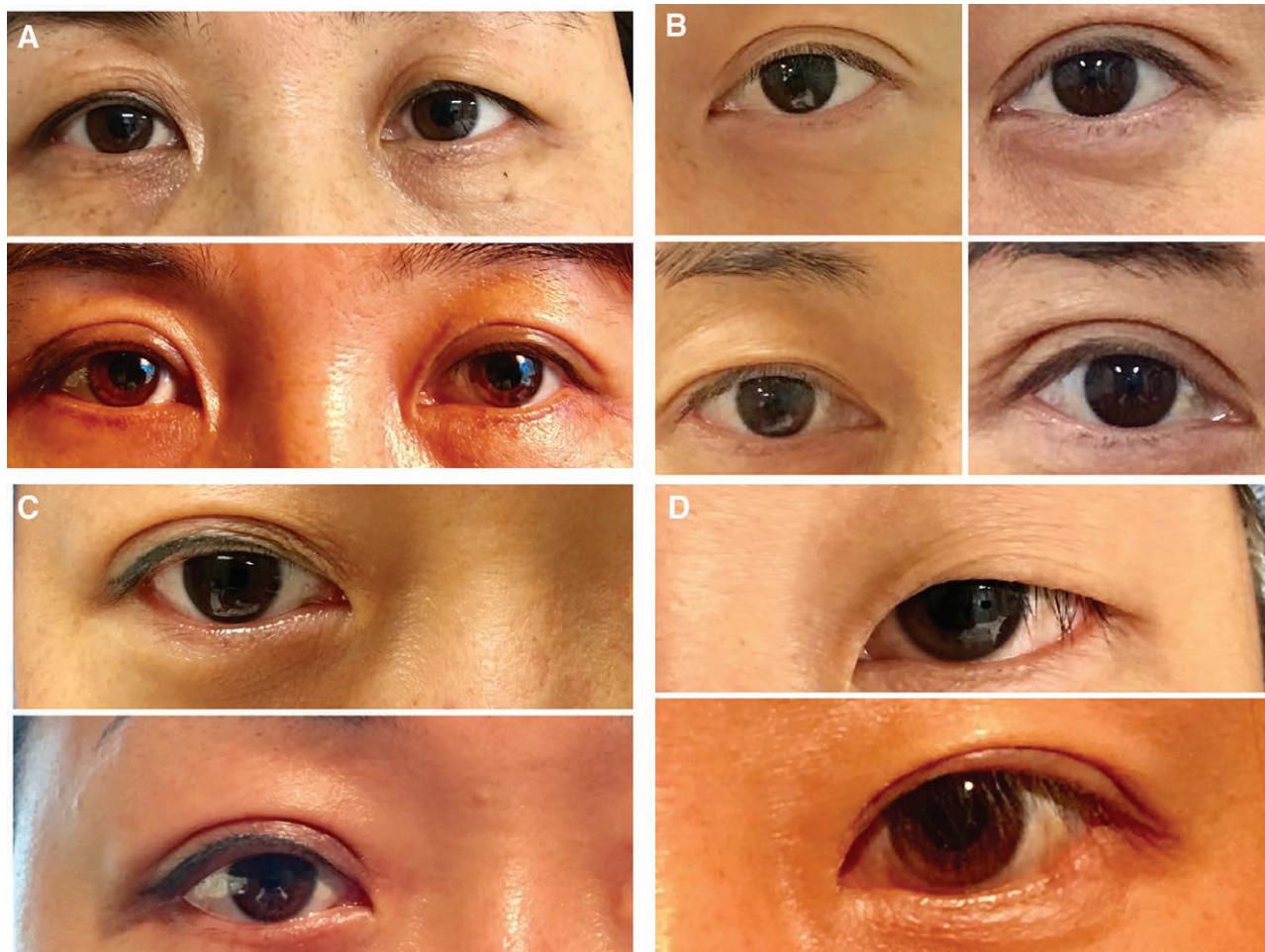


Fig. 10. Pre- and postoperative views. A, 42-y-old female for primary Asian blepharoplasty, who preferred nasally joining crease shape, and medium crease height of 7 mm. B, 36-y-old female who presented with crease asymmetry of left eye 8.5 mm crease height, right eye 5.0 mm crease height (left column: preoperative); preferred staying with parallel shape, and chose 7.5 mm crease height (right column: postoperative views). C, 40-y-old female has permanent eyeliner, with crease height of 8.5 mm and pretarsal skin wrinkling; prefer stay with parallel shape and set to 7.5 mm crease height (right eye shown here). D, 29-y-old female for primary Asian blepharoplasty. Preferred medium crease height of 7.0 mm, and parallel crease shape (left eye shown here).

Benchmark

- Avoid use of any buried permanent anchoring sutures that are nonabsorbable.
- Avoid penetrating the full thickness of levator aponeurosis.
- Avoid encircling the orbicularis oculi, levator and Mueller's within any permanent buried suture loops. Each of these 3 layers serves a different function and needs their own space; bonding them together creates an undesirable union.

Asian blepharoplasty cases (Figure 10) should be evaluated not merely on whether a crease is seen soon after a procedure, but also in regard to whether the crease develops migration, shallowness or developed any ptosis subsequently. Follow-up period as long as 1 year is needed. The parameters of height, shape, continuity and permanence and incidence of various complications are cornerstones to which each variant of double eyelid surgery techniques should be judged by.

Despite a low touch-up rate of only 2.5% in this limited article, crease formation seemed more predictable for the over-30's age group than the under-30's as there may be more interfering preaponeurotic fat in the younger group. Still, the series' 97.4% crease-formation rate is only possible due to strict adherence to various benchmarks discussed here, mindful of both facilitating and impeding factors.

Limitations

This analysis is based on data from a solo practitioner in a diverse Southern California setting. This may be its strength since the evaluator, comprehensive eye examiner and surgeon are the same individual. It benefits from the constancy and long-term follow-ups feasible over a 12-year period. The surgeon used a specific external incisional technique that best fits anatomic findings and physiologic principles and adheres to his strict benchmarks. For the precise dilemma that it is difficult to fully gauge patients' satisfaction ratings, each patient

was encouraged to have at the minimum a 2- to 3-month postoperative return visits following their initial 1-week visit for suture removal, and often extended to 1 year. The practice encouraged patients to return for any complaints or if there should be any reason to desire further improvement. Patients who may require postoperative touch-ups by the author are encouraged to have this performed at 6–12 months out.

CONCLUSIONS

Asian blepharoplasty via trapezoidal debulking of preaponeurotic platform provides an optimal balance between achieving anatomic goals, improving efficiency of upper lid functions while enhancing the eyelids' aesthetic appearance. The factors discussed here (aponeurotic attachment, selective block reduction of tissues, precise positioning of the crease-forming nano-points, detection of latent ptosis and avoidance of locking sutures that create Faden-like effect) together with an understanding of the 5:7 ratio of equivalence between Tilted crease height (Tch) to anatomic crease height has served the author well through the years. These are principles that contribute to a successful upper blepharoplasty. This paper on Asian blepharoplasty presented a logical outcome analysis, discussion of conceptual and practical concerns and best-adopted solutions for this highly specialized form of aesthetic eyelid surgery.

William P. D. Chen, MD
18 Endeavor, Suite 305
Irvine, CA 92618
E-mail: wpdchen@ucla.edu

REFERENCES

- Chen WP. Literature on double eyelid surgeries: appendix 1,2,3. In: *Asian Blepharoplasty and the Eyelid Crease*. 3rd ed. Edinburgh/New York: Elsevier; 2016:345–365.
- Chen WP. Concept of triangular, trapezoidal, and rectangular debulking of eyelid tissues: application in Asian blepharoplasty. *Plast Reconstr Surg*. 1996;97:212–218.
- Collin JR, Beard C, Wood I. Experimental and clinical data on the insertion of the levator palpebrae superioris muscle. *Am J Ophthalmol*. 1978;85:792–801.
- Cheng J, Xu FZ. Anatomic microstructure of the upper eyelid in the oriental double eyelid. *Plast Reconstr Surg*. 2001;107:1665–1668.
- Morikawa K, Yamamoto H, Uchinuma E, et al. Scanning electron microscopic study on double and single eyelids in Orientals. *Aesthetic Plast Surg*. 2001;25:20–24.
- Whitnall SE. *Anatomy of the Human Orbit and Accessory Organs of Vision*. 2nd ed. London, United Kingdom: Oxford University Press; 1932:140–148.
- Siegel R. Surgical anatomy of the upper eyelid fascia. *Ann Plast Surg*. 1984;13:263–273.
- Stasior GO, Lemke BN, Wallow IH, et al. Levator aponeurosis elastic fiber network. *Ophthalmic Plast Reconstr Surg*. 1993;9:1–10.
- Chen WP. The concept of a glide zone as it relates to upper lid crease, lid fold, and application in upper blepharoplasty. *Plast Reconstr Surg*. 2007;119:379–386.
- Fernandez LR. Double eyelid operation in the oriental in Hawaii. *Plast Reconstr Surg Transplant Bull*. 1960;25:257–264.
- Boo-Chai K. Further experience with cosmetic surgery of the upper eyelid. Paper presented at: Proceedings of the Third International Congress of Plastic Surgery, Reprinted from Excerpta Medica International Congress Series No. 66; 1963: 518.
- Boo-Chai, K. *Secondary Blepharoplasty in Orientals: Problems in Plastic and Reconstructive Surgery*. Philadelphia, PA: Lippincott; 1991:520–535.
- Boo-Chai K. Perioperative bleeding in the pre-tarsal (post-aponeurotic) space in oriental blepharoplasty. *Br J Plast Surg*. 2001;54:370.
- Mutou Y, Mutou H. Intradermal double eyelid operation and its follow-up results. *Br J Plast Surg*. 1972;25:285–291.
- Chen WPD. Asian blepharoplasty: update on anatomy and technique. *Ophthal Plast Reconstr Surg*. 1987;3:135.
- McCurdy JA. *Cosmetic Surgery of the Asian Face*. New York, NY: Thieme Medical Publishers; 1990.
- Flowers RS. Upper blepharoplasty by eyelid invagination: anchor blepharoplasty. *Clin Plast Surg*. 1993; 20:193.
- Chen WPD. In: Putterman AM, ed. *Cosmetic Oculoplastic Surgery*. Philadelphia, PA: WB Saunders; 1999;101–111.
- Chen, WPD. Aesthetic eyelid surgery in Asians: an east-west view. *Hong Kong J Ophthalmol*. 2000;3:27.
- Chen WPD. *Oculoplastic Surgery: The Essentials*. New York, NY: Thieme Medical Publishers; 2001.
- Chen WPD, Khan JA, eds. *Color Atlas of Cosmetic Oculoplastic Surgery*. 2nd ed. Elsevier Sciences; 2014.
- Shirakabe, Y. Mikamo's double-eyelid operation: the advent of Japanese aesthetic surgery (Discussion). *Plast Reconstr Surg*. 1997;99:668.
- Kikkawa DO, Kim JW. Asian blepharoplasty. *Int Ophthalmol Clin*. 1997;37:193–204.
- Tsurukiri, K. Double eyelid plasty: reliability and unfavorable results to the patients (Abstract). *Aesthetic Plast Surg*. 1999;20:38.
- Jeong S, Lemke BN, Dortzbach RK, et al. The Asian upper eyelid: an anatomical study with comparison to the Caucasian eyelid. *Arch Ophthalmol*. 1999;117:907–912.
- Homma K, Mutou Y, Mutou H, et al. Intradermal stitch for orientals: does it disappear? *Aesthetic Plast Surg*. 2000;24:289.
- Kim BG, Youn D, Yoon ES, et al. Unexpected bleeding caused by arterial variation inferolateral to levator palpebrae. *Aesthetic Plast Surg*. 2003;27:123–125.
- Hwang K, Kim BG, Kim YJ, et al. Lateral septoaponeurotic artery: source of bleeding in blepharoplasty performed in Asians. *Ann Plast Surg*. 2003;50:156–159.
- Kawai K, Imanishi N, Nakajima H, et al. Arterial anatomical features of the upper palpebra. *Plast Reconstr Surg*. 2004;113: 479–484.
- Chen WPD: Beveled approach for revisional surgery in Asian blepharoplasty. *Plast Reconstr Surg*. 2007;120:545–552; discussion 553–555.
- Chen WPD. Video 1 primary double eyelid surgery—trapezoidal debulking of upper eyelid tissues. *Plast Reconstr Surg Glob Open*. 2018;6:e1780.
- Chen WPD. Video 2 Revisional Asian blepharoplasty—bevelled approach and resetting of eyelid lamellas. *Plast Reconstr Surg Glob Open*. 2018;6:e1785.
- Chen WP. Visual, physiological, and aesthetic factors and pitfalls in Asian blepharoplasty. *Aesthet Surg J*. 2016;36:275–283.
- Zubiri JS. Correction of the Oriental eyelid. *Clin Plast Surg*. 1981;8:725–737.
- Kruavit A. Asian blepharoplasty: an 18-year experience in 6215 patients. *Aesthet Surg J*. 2009;29:272–283.
- Chen WP, Park JD. Asian upper lid blepharoplasty: an update on indications and technique. *Facial Plast Surg*. 2013;29:26–31.
- Zubiri JS. Subdermal placement of sutures in double eyelid surgery. *Aesthet Surg J*. 2013;33:722–732.

38. Chang SH, Chen WPD, Cho IC, Ahn TJ. Comprehensive review of Asian cosmetic upper eyelid oculoplastic surgery: Asian blepharoplasty and the like. *Arch Aesthetic Plast Surg*. 2014;20:129–139.
39. Chen WPD. Chapter 25. In: *Asian Blepharoplasty and the Eyelid Crease*. 3rd ed. Edinburgh/New York: Elsevier Science; 2016.
40. Rohrich RJ, Villanueva NL, Afrooz PN. Refinements in upper blepharoplasty: the five-step technique. *Plast Reconstr Surg*. 2018;141:1144–1146.
41. Chen WPD. *Asian Blepharoplasty and the Eyelid Crease*. 3rd ed. Elsevier Science; 2016.
42. Hwang K, Kim DJ, Chung RS, et al. An anatomical study of the junction of the orbital septum and the levator aponeurosis in Orientals. *Br J Plast Surg*. 1998;51:594–598.
43. Lee JS, Park WJ, Shin MS, et al. Simplified anatomic method of double-eyelid operation: septodermal fixation technique. *Plast Reconstr Surg*. 1997;100:170–178; discussion 179.
44. Reid RR, Said HK, Yu M, et al. Revisiting upper eyelid anatomy: introduction of the septal extension. *Plast Reconstr Surg*. 2006;117:65–66; discussion 71.
45. Hwang K, Huan F, Kim DJ. Levator sheath revisited. *J Craniofac Surg*. 2012;23:1476–1478.
46. Kim HS, Hwang K, Kim CK, et al. Double-eyelid surgery using septoaponeurosis junctional thickening results in dynamic fold in Asians. *Plast Reconstr Surg Glob Open*. 2013;1:1–9.
47. Meyer DR, Linberg JV, Wobig JL, et al. Anatomy of the orbital septum and associated eyelid connective tissues. Implications for ptosis surgery. *Ophthalmic Plast Reconstr Surg*. 1991;7:104–113.
48. Press UP, Schayan-Araghi K, Juranek R, et al. Resection of the Müller muscle. Indications, technique and results. *Ophthalmologie*. 1994;91:533–535.
49. Bartley GB, Lowry JC, Hodge DO. Results of levator-advancement blepharoptosis repair using a standard protocol: effect of epinephrine-induced eyelid position change. *Trans Am Ophthalmol Soc*. 1996;94:165–173; discussion 174.
50. Morris CL, Morris WR, Fleming JC. A histological analysis of the Müllerectomy: redefining its mechanism in ptosis repair. *Plast Reconstr Surg*. 2011;127:2333–2341.
51. Maheshwari R, Maheshwari S. Müller's muscle resection for ptosis and relationship with levator and Müller's muscle function. *Orbit*. 2011;30:150–153.
52. Ranno S, Sacchi M, Gonzalez MO, et al. Evaluation of levator function for efficacy of minimally invasive and standard techniques for involutional ptosis. *Am J Ophthalmol*. 2014;157:209.e1–213.e1.
53. Rüfer F, Schröder A, Erb C. White-to-white corneal diameter: normal values in healthy humans obtained with the Orbscan II topography system. *Cornea*. 2005;24:259–261.
54. Johnson CC. Epicanthus. *Am J Ophthalmol*. 1968;66:939–946.
55. Recent literature on epicanthoplasty (listing 16 papers in English): appendix 4. In: *Asian Blepharoplasty and the Eyelid Crease*. 3rd ed. Edinburgh/New York: Elsevier; 2016: 366–371.
56. Seo JD, Kim JH, Pak CS, et al. Medial epicanthoplasty using the “inside-out” technique. *J Plast Surg Hand Surg*. 2014;48:139–142.
57. Chung YJ, Han KE, Park BY. Restoration of complicated epicanthus: modified reverse skin redraping with mini-epicanthoplasty for rescue in unsatisfied epicanthoplasty patients. *Ann Plast Surg*. 2017;78:613–617.
58. Yoon CH, Na MH, Kim WS, et al. Epicanthoplasty with three-dimensional Z-Plasty. *J Korean Soc Aesthetic Plast Surg*. 1997;3:67–73.
59. de Decker W. The Faden operation. When and how to do it. *Trans Ophthalmol Soc UK*. 1981;101 (Pt 2):264–270.
60. Schittkowski MP, Naxer S. Faden operations - indications beyond esotropia and surgical results. *Klin Monbl Augenheilkd*. 2012;229:995–999.
61. Akar S, Gokyigit B, Sayin N, et al. Medial rectus Faden operations with or without recession for partially accommodative esotropia associated with a high accommodative convergence to accommodation ratio. *Br J Ophthalmol*. 2013;97:83–87.
62. Koornneef L. Details of the orbital connective tissue system in the adult. *Acta Morphol Neerl Scand*. 1977;15:1–34.
63. Koornneef L. Eyelid and orbital fascial attachments and their clinical significance. *Eye*. 1988;2:130–134.
64. Clark RA, Miller JM, Demer JL. Location and stability of rectus muscle pulleys. Muscle paths as a function of gaze. *Invest Ophthalmol Vis Sci*. 1997;38:227–240.
65. Clark RA, Isenberg SJ, Rosenbaum AL, et al. Posterior fixation sutures: a revised mechanical explanation for the fadenoperation based on rectus extraocular muscle pulleys. *Am J Ophthalmol*. 1999;128:702–714.
66. Clark RA, Miller JM, Demer JL. Three-dimensional location of human rectus pulleys by path inflections in secondary gaze positions. *Invest Ophthalmol Vis Sci*. 2000;41:3787–3797.